

Median Nerve Entrapment in the Forearm: Diagnosis and Treatment

William B. Ericson, Jr., MD, FACS

www.wbericson.org

Introduction

Median nerve entrapment in the forearm (MNF) is an increasingly common problem that is particularly difficult to diagnose and treat. MNF presents as **vague, intermittent hand pain**, and the perception of **hand weakness**. These complaints unfortunately overlap with many other common hand problems. Objective physical findings are subtle, and exhaustive workups are unrevealing. In spite of these challenges, MNF is a diagnosable condition, but successful treatment depends on a holistic approach to the patient and an appreciation of the context in which a common anatomic variation can become an exasperating clinical problem. A diagnostic process, classification system, and results are described, and a treatment protocol is proposed.

Anatomy

The anterior interosseous nerve (AIN) diverges from the median nerve just distal to the elbow, and innervates the FPL, FDP IF, and PQ muscles, and provides a sensory branch to the volar wrist and thumb CMC area. Pressure on the median nerve from common anatomic variations of muscles around the elbow can attenuate the motor output of the AIN, causing demonstrable weakness of the FPL and FDP IF. As the pressure increases, patients experience pain and occasionally numbness in distribution of the distal median nerve.

Diagnosis

The diagnosis of MNF is established by the following physical finding:

- Isolated weakness of the FPL and FDP IF.

The strength of these muscles must be tested at their **resting length**, which for the fingers is with the **wrist neutral** and the **MP/PIP/DIP joints flexed**. To test the FPL, the **wrist must be neutral**, and the **thumb must be abducted** from the palm. Patients who have adapted to AIN weakness will tend to extend the wrist as the FDP IF is tested, and will also tend to adduct and flex the thumb as the FPL is tested. These adaptive maneuvers must be anticipated and prevented by the examiner to assess the true strength of these muscles. Almost always associated with AIN weakness are the following additional findings: 1) numbness in the hand in less than one minute of sustained full pronation of the forearm against firm resistance, and 2) tenderness at the site of the takeoff of the AIN, with numbness in the hand in less than one minute with firm palpation in this area. All 100 patients in this presentation had these three findings bilaterally. Electrodiagnostic studies are unhelpful.

Classification System

Patients with AIN weakness tend to adapt to the weakness rather than seek treatment. Dynamometer grip and pinch strength remain normal, as the weakness is evident only when adaptation is prevented, such as pinching with the wrist flexed. Patients describe particular difficulty opening small jars, pill bottles, potato chip bags, peel packs, or putting on jewelry, and may complain of "dropping things." Many patients with MNF never progress to hand pain or numbness, but over time may develop joint problems in the index finger and thumb from altered pinch mechanics. Which joints wear out depends on their mechanism of adaptation.

Patients with activity-related hand pain from MNF modify their activities to prevent pain. The pain is a deep, vague pain that is in the hand, not at the site of compression near the elbow. Symptoms are provoked by activities involving sustained pronation of the forearm, such as extensive writing, typing, using a mouse or a cell phone. These patients seek treatment only when they can't modify their activities sufficiently or when they have significant pain in spite of modification. The pain varies in intensity, and can be quite severe at times. It is not an inflammatory process, and the pain is not relieved by NSAIDs. The pain is not related to tendon excursion, and is not relieved by splints. The appearance of the hand remains normal even when extremely painful. Numbness is relatively uncommon, except at night, when the hand may become completely numb with any pressure on the forearm.

Acute AIN palsies occur following minor trauma to the forearm in patients with pre-existing subclinical MNF. The palsy is preceded by severe pain in the distal median nerve distribution from ischemia of the median nerve at the bifurcation of the pronator teres muscle, infarction of the AIN ensues. These patients always have positive EMGs, and always have at least Grade 2 findings on the contralateral side.

Table 1. Classification of Median Nerve Entrapment in the Forearm

Grade	Complaints		Exam		Test	
	Hand Weakness	Hand Pain	Hand Numbness	Weak FPL, FDP IF	Numbness Provocable	EMG abnormal
Normal	0	No	No	No	No	No
Subclinical	1	No	No	No	Yes	No
Subclinical	2	No	No	No	Yes	Yes
Mild	3	Yes	No	No	Yes	Yes
Moderate	4	Yes	Yes	No	Yes	Yes
Severe	5	Yes	Yes	Yes	Yes	Yes
Acute AIN palsy	6	Yes	Yes	Yes	Yes	Yes
Post-acute	7	Yes	No	No	Yes	Yes

Methods

100 consecutive patients underwent neurolysis of the median nerve in the forearm by the same surgeon and are reviewed retrospectively. Follow-up ranged from 1 week to 2 years, with 94 patients seen for at least 2 months, and 73 for at least 6 months. All had bilateral findings of MNF of at least Grade 2, and 17 eventually had bilateral surgery, for a total of 117 procedures. 88 patients underwent additional simultaneous procedures, 47 of which included carpal tunnel release. There were 9 thumb CMC joint ligament reconstructions and 9 capsulodeses for wrist instability.

Results

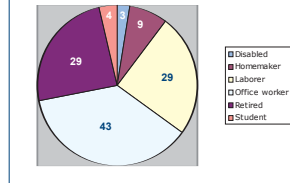
There were 44 males and 56 females. Age ranged from 16 to 83 years. Approximately one third were retired, one third were laborers, and 43% were office workers. More than half of the patients had symptoms for at least 2 years. Only 5 patients complained of forearm pain, and this complaint was only seen in patients with concurrent thoracic outlet symptoms and obesity, cervical spondylosis, or depression. EMGs of the FPL, PQ and PT were almost always normal.

Surgery was performed on an outpatient basis. No postop casts, splints, or hand therapy were necessary following this procedure, even if the pronator teres was lengthened. All patients had immediate return of the strength of the FPL and FDP IF in the recovery room, except for the one AIN palsy patient, whose strength was better but not normal. Following 92 of the procedures, patients reported complete relief of their symptoms. Following 19 of the procedures, patients noted considerable improvement, which often made management of their comorbidities easier. 6 patients noted no improvement, despite the fact that MNF could no longer be demonstrated in their arms. Only one of the 6 failures was in a patient on workmen's compensation. No one was worse after surgery.

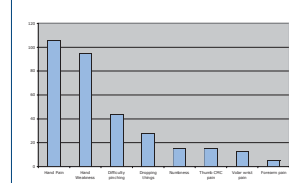
There were three complications: 1 cellulitis, 2 temporary neurapraxias of the medial antebraclial cutaneous nerve, and 1 urinary retention. There were no deep infections, hematomas, recurrences or pain syndromes.

All patients who were working at the time of surgery went back to work at the same job, usually within a few weeks. Only 3 patients were operated on under workmen's compensation insurance; 2 went back to work promptly and the other remained on disability for other reasons. 2 patients were on disability for neck injuries and remained on disability after surgery.

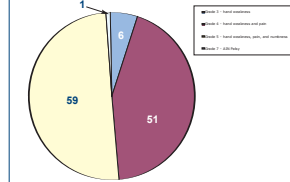
Occupation



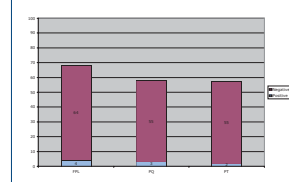
Chief Complaints



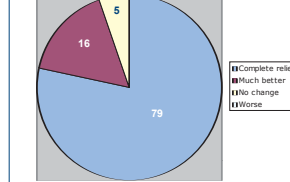
Preop Classification



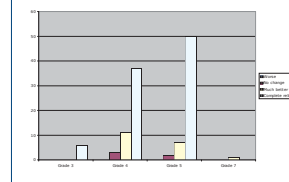
EMG <5% positive



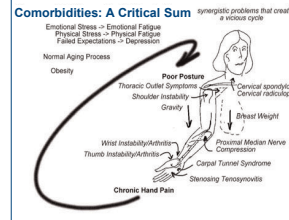
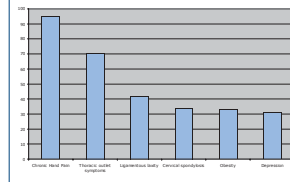
Results



Results By Grade



Comorbidities



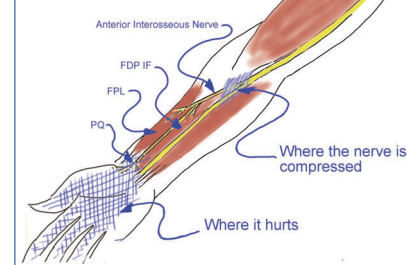
Discussion

MNF is a subtle diagnosis that requires knowledge of very specific anatomy and applied biomechanics. Commonly accepted objective tests such as radiographs, dynamometer grip and pinch strength, and EMGs are particularly poor for this assessing this diagnosis. One must treat the patient rather than the test result, a challenging task for physicians who believe in quantitative data, and who are prone to rely more firmly on this data when confronted with clinical uncertainty and vague, variable symptoms that do not make sense. Given the ubiquity of pronated activities (writing, keyboards, cell phones), frequent multitasking, an aging population, and the simultaneous epidemics of obesity and depression, it is no surprise that large numbers of patients with anatomic variations at the elbow are experiencing intermittent hand pain without relief.

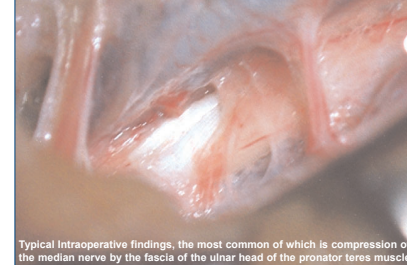Current Protocol

Patients presenting with vague, intermittent hand pain are examined for specifically for AIN weakness in the manner described. When found, patients are assumed to have a "critical sum" of comorbidities, which are then addressed systematically. Reflexes are checked to assess for cervical myelopathy. Patients are made aware that postural issues can result in hand pain in people with otherwise subclinical MNF. Patients are encouraged to carry less weight emotionally as well as physically. Weight loss and aerobic exercise are encouraged. Thoracic outlet symptoms, poor posture, cervical spondylosis, and shoulder instability are addressed with physical therapy. Patients with numbness and a positive Phalen's test are given a steroid injection into the carpal tunnel, and electrodiagnostic studies are performed. If the electrodiagnostic studies are normal and there is no response to the steroid injection, carpal tunnel syndrome is effectively ruled out. Activities are modified to avoid sustained pronation of the forearm, using wrist rests, hands-free phones, ergonomic mice, split keyboards, alternate input devices, and varying activities. Many patients will have tremendous relief of their pain with these measures, although AIN weakness remains. Patients who address these issues satisfactorily but continue to have hand pain with pronation are candidates for surgery and generally do well with intervention.

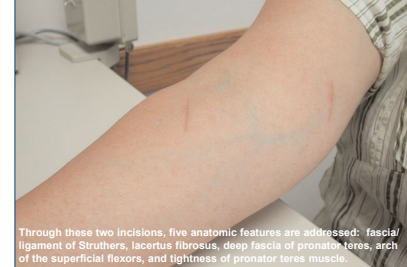Basic Anatomy



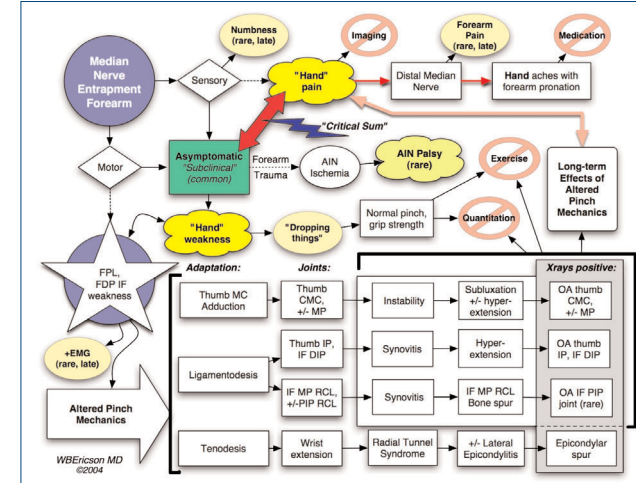
Typical Intraoperative Findings



Typical scars



Through these two incisions, five anatomic features are addressed: fascia/ligament of Struthers, lacertus fibrosus, deep fascia of pronator teres, arch of the superficial flexors, and tightness of pronator teres muscle.



Conclusions

"Pronator Syndrome" as previously described in medical literature does not exist. MNF does exist, can be diagnosed and treated successfully, but the patient must be addressed as a whole person rather than an anatomic variation at the elbow.

The key to understanding MNF is the application of the Blix curve to the actual resting lengths of the FPL and FDP IF. Previous descriptions of testing these muscles do not apply this information, and do not address adaptive maneuvers by the patient.

Subclinical MNF is very common, and does not need to be treated. However, it can easily become a clinical problem that, unrecognized, defies both diagnosis and intervention.

If symptoms progress, MNF causes:

- Subtle weakness that patients may not note or complain of, but that can be demonstrated on physical exam
- Vague, intermittent hand pain, in the distribution of the distal median nerve, not at the site of compression near the elbow.
- Occasional numbness in the hand, more commonly if the patient has additional nerve-related issues such as CTS or poor posture.
- No forearm pain
- No reliable EMG abnormality, unless the nerve actually infarcts

Operating only on patients with positive EMGs means that 95% of the patients with hand pain from MNF will have no chance of relief.

The transition from "subclinical" to "clinical" is associated with a "critical sum" of the following factors:

- Normal aging process
- Chronic hand pain
- Sustained or repetitive pronation of the forearm
- Thoracic outlet symptoms
- Cervical spondylosis/radiculopathy
- Obesity
- Depression
- Ligamentous laxity

Any patient with non-specific hand pain should be assessed by this protocol, as should patients who have failed other hand surgery such as CTR because of persistent "hand pain" and "hand weakness."

Any therapy or intervention that either directly or indirectly improves the patient's posture will tend to decrease the amount of hand pain experienced.

Any problem that directly or indirectly affects the patient's posture adversely will tend to increase the amount of hand pain experienced.

Patients return to work quickly and predictably if surgery is performed under their regular health insurance.

Patients don't "heal" this so-called "repetitive strain injury" because there is no injury. The hand pain associated with MNF represents a conflict between patients' anatomy and their activities, and it occurs on a background of complex psychosocial issues, the normal aging process and the cumulative effect of gravity on the arm and body.

This data is consistent with previous studies that show an association between psychosocial factors and hand pain, but it also provides an anatomic explanation for a previously unknown source of pain and an anatomically-based treatment protocol that has a high success rate and low complication rate in non-workmen's compensation patients.

This is not the answer to all questions about unexplained hand pain; just a piece of the puzzle.